

# Mediastinal paraganglioma with subsequent intracranial metastasis: A case report

ENIS ÖZYAR<sup>1</sup>, EREN ÇETİN<sup>1</sup>, MİNE GENÇ<sup>2</sup>, AYŞEGÜL ÜNER<sup>3</sup>, I. LALE ATAHAN<sup>1</sup>

<sup>1</sup>Hacettepe University Institute of Oncology, Department of Radiation Oncology, Ankara, <sup>2</sup>Selçuk University Medical School, Department of Radiation Oncology, Konya, <sup>3</sup>Hacettepe University Medical School, Department of Pathology, Ankara-Turkey

## ABSTRACT

A 41-year-old man with unresectable mediastinal paraganglioma who subsequently developed multiple intracranial metastases is presented. This is the first case of intracranial metastases from mediastinal paraganglioma in literature. In general, intracranial metastases from paraganglioma of any location in the body are extremely rare, with only 3 other cases in the literature. [Turk J Cancer 2005;35(1):32-34]

## KEY WORDS:

Paraganglioma, intracranial metastasis, radiotherapy

## INTRODUCTION

Paragangliomas are tumors of paraganglia which consist of neuroepithelial cells. These tumors are most commonly found in the temporal bone or cervical region. Other locations are skull base, mediastinum, abdomen and retroperitoneum. Paragangliomas are classified as chromaffin (produces catecholamines) and nonchromaffin tumors (chemodectomas or glomus body tumors) (1). Clinical presentation depends on the involved site and whether or not tumor produces any active substances. Predominant spread pattern of these low-grade tumors is local invasion. Metastasis occur in 2-5% of the cases (2).

Primary treatment of paragangliomas is radiotherapy and/or surgery depending on the site and extension of the lesion. The largest series with 84 patients reported 90% and 73% of actuarial control rates for 10 and 25 years, respectively (3). In an analysis of dose-response relation for paragangliomas, the recurrence rate was 25% when the radiation dose was less than 40 Gy (4). Local recurrence is rare with higher radiation doses (4).

Mediastinal paragangliomas are very rare neoplasms. Therefore, there is limited experience with the clinical behaviour of these tumors (5-7). Here we report a case of mediastinal paraganglioma with subsequent intracranial metastases.

## CASE REPORT

A 41-year-old man was admitted to the hospital with back pain. Computerised Tomography (CT) revealed a 7.5x6x6 cm mass in the upper mediastinum (Figure 1). Thoracotomy was performed and the mass was found to be unresectable invading the left pulmonary artery. There were also paratracheal and precarinal lymphadenopathies of which the largest has the diameter of 3 cm. Pathological examination showed paraganglioma. The immunohistochemical studies showed that the tumor cells were strongly positive for chromogranin and neuron specific enolase. Negative reaction for cytokeratin, S-100, synaptophysin, HMB-45 and PAP was detected. The patient received radiotherapy with 6 MV X-rays. A total doses of 48 Gy and 60 Gy were delivered in 2 Gy daily fractions to the mediastinal region and to the tumor, respectively. Six months after completing radiotherapy partial response was observed. However, the patient complained of headache and syncope one month later and magnetic resonance imaging (MRI) revealed multiple intracranial metastases which show contrast enhancement, in parietal and parietooccipital lobes with the largest being 22 mm in dimension (Figure 2). A palliative whole cranial radiotherapy was applied with 3 Gy daily fractions for the total dose of 30 Gy. Cranial MRI was performed 6 months after radiotherapy and partial response was observed. The maximum diameter of intracranial lesions decreased from 22 mm to 7 mm. Thoracal CT revealed stable disease when compared with the previous examination.

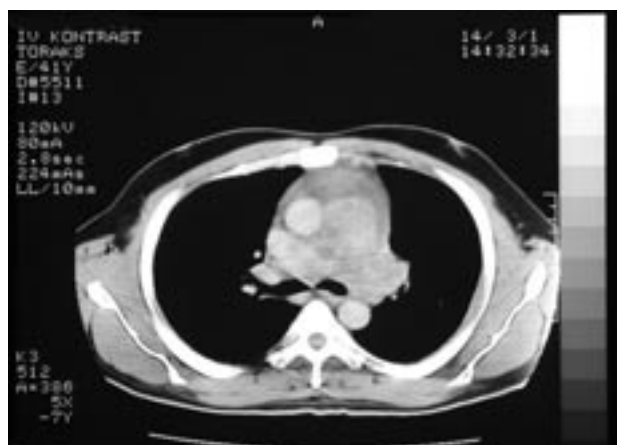


Fig 1. Magnetic Resonance Imaging demonstrating intracranial metastatic lesions which show contrast enhancement

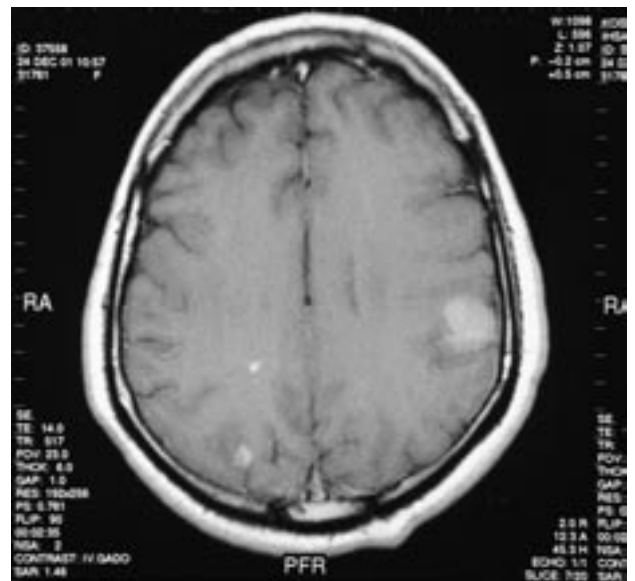


Fig 2. Computerised Tomography showing a mass in the anterior mediastinum

## DISCUSSION

Paragangliomas are rare neoplasms which usually don't show aggressive clinical behaviour. Mediastinal location is rare relative to other sites. The retrospective study of 16 cases of mediastinal paragangliomas concluded that aggressive behaviour correlates only with the extent of local infiltration (5). No clinical, histological or immunohistochemical features (chromogranin, S-100, leukephalin, neurofilament protein, keratin) were found to predict aggressive behaviour. Although majority of these tumors have an indolent behaviour, the patients might develop distant metastasis. In a review of 30 cases, a slight predominance for men and average age of 29 were reported (6). Fifteen (48%) patients had clinical symptoms related to excess catecholamine secretion, 7 (23%) patients had multiple tumors, 13 were alive without disease during 2.2 years of follow-up and 2 patients developed distant metastases. In the other review of 41 patients, 8 patients died of tumor (4 of them with metastases) and 19 were alive without disease 5 months to 21 years after treatment (7). Mediastinal paragangliomas are usually unresectable and nonsecretory tumors and associated with larger tumor size, older age, longer duration of symptoms.

In the literature, there are 3 cases of intracranial metastases of paraganglioma. The first case reported was a patient with cervical paraganglioma who developed multiple intracranial and intraspinal metastases 7 months after subtotal resection and radiotherapy (8). The second case was a cauda equina paraganglioma with subsequent intracranial and intraspinal metastases (9). Both cases reported had tumors situated adjacent to central nervous system and metastasis might had been due to local invasion which is predominant mode for paragangliomas. The third case was

reported as unknown primary with multiple organ metastases including brain (10).

As a result, intracranial metastasis due to paragangliomas may occur, even rare. As far as we know, mediastinal paraganglioma with subsequent intracranial metastasis has not been previously reported. Clinical course of metastatic paragangliomas differs. Surgery and/or radiotherapy are the choices of treatment, despite a little is known about effective treatment of metastatic paragangliomas. Chemotherapy has no defined role for treatment at any stage.

---

## References

1. Sobol SM, Dailey JC. Familial multiple cervical paragangliomas: Report of a kindred and review of the literature. *Otolaryngol Head Neck Surg* 1990;102:382-90.
2. Konefal JB, Pilepich MV, Spector GJ, et al. Radiation therapy in the treatment of chemodectomas. *Laryngoscope* 1987;97:1331-5.
3. Powell S, Peters N, Harmer C. Chemodectoma of the head and neck: Results of treatment in 84 patients. *Int J Radiat Oncol Biol Phys* 1992;22:919-24.
4. Kim JA, Elkon D, Lim M, et al. Optimum dose of radiotherapy for chemodectomas of the middle ear. *Int J Radiat Oncol Biol Phys* 1980;6:815-9.
5. Moran CA, Suster S, Fishback N, et al. Mediastinal paragangliomas, a clinicopathologic and immunohistochemical study of 16 cases. *Cancer* 1993;72:2358-64.
6. Gallivan MV, Chun G, Lack EE. Intrathoracic paravertebral malignant paraganglioma. *Arch Pathol Lab Med* 1980;104:46-51.
7. Olson JL, Salyer WR. Mediastinal paraganglioma (aortic body tumor). *Cancer* 1978;41:2405-12.
8. Blades DA, Hardy RW, Cohen M. Cervical paraganglioma with subsequent intracranial and intraspinal metastases. Case report. *J Neurosurg* 1991;75:320-3.
9. Roche PH, Figarella-Branger D, Regis J, et al. Cauda equina paraganglioma with subsequent intracranial and intraspinal metastases. *Acta Neurochir (Wien)* 1996;138:475-9.
10. Tomita H, Yamashita H, Tamaki N. Malignant paraganglioma with intracranial metastasis: a case report. *No Shinkei Geka* 1996;24:1045-8.