

Cadherin/catenin expression in squamous lesions of uterine cervix

HADICE ELIF PESTERELI¹, GÜLGÜN ERDOĞAN¹, TAYYIP ŞİMŞEK², ŞEYDA KARAVELI¹

Akdeniz University, Departments of ¹Pathology and ²Obstetrics and Gynecology, Antalya-Turkey

ABSTRACT

The aim of this study is to reveal the altered expression of E- and P-cadherin, α - and β -catenin in cervical squamous cell carcinoma progression from dysplastic lesions lesion to invasive squamous cell carcinoma. Immunohistochemical method was used in 25 L-SIL (CIN I), 25 H-SIL (CIN II-III) and 30 invasive squamous cell carcinomas (SCC). E-cadherin was detected in 91.7%, 41.7%, 6.9% of L-SIL, H-SIL and invasive squamous cell carcinomas, respectively. The difference between L-SIL, H-SIL and SCC was statistically significant ($p=0.0001$). The expression of P-cadherin and α -catenin was reduced significantly ($p=0.009$ for P-cadherin, $p=0.0001$ for α -catenin). β -catenin expression was revealed in all lesions with nearly the same frequency. Loss of adhesion proteins, E-cadherin, P-cadherin and α -catenin is observed in cervical squamous cell carcinoma progression. The presence of β -catenin in H-SIL and invasive carcinomas might suggest its role in tumor progression by its effect in Wnt signaling pathway in cervical carcinomas. [Turk J Cancer 2006;36(2):64-68].

KEY WORDS:

Cadherins, cervix neoplasms, cervix dysplasia

INTRODUCTION

Cadherins are transmembrane glycoproteins involved in a Ca-dependent cell-cell adhesion mechanism. They play an important role in morphogenesis and in maintenance of tissue architecture (1). Three types of cadherins have been identified: E-, P- and N-cadherin according to their tissue distribution and binding specificities (2). Cadherins are anchored to the cytoskeleton via associated cytoplasmic proteins, α -catenin, β -catenin and γ -catenin (3). Loss of cell adhesion is important in tumor progression. Disturbance of cadherin-catenin mechanism favors tumor invasion. β -catenin also activates transcription of growth promoting genes in the nucleus which might act as a proliferating factor in tumors (4).

Preneoplastic lesion in cervical carcinoma is well known. The aim of this study is to show the altered distribution of adhesion molecules in precancerous squamous lesions and in squamous carcinomas of uterine cervix.

MATERIALS AND METHODS

Formalin-fixed, paraffin embedded representative tissue sections of 25 low grade squamous intraepithelial lesion (L-SIL) (CIN I), 25 high grade squamous intraepithelial lesion (HSIL) (CIN II-III) and 30 invasive squamous cell carcinoma were retrieved from the archive of Pathology Department, Akdeniz University. We applied the Bethesda

system to histopathology to classify the precancerous squamous lesions. Sections were dewaxed, rehydrated in graded alcohols, and immunostained using a standard streptavidin-biotin immuno-peroxidase method. Monoclonal antibodies against E-cadherin (36 B5, 1:20 dilution, Neomarkers, USA), P-cadherin (polyclonal, 1:100 dilution, Santa-Cruz, USA), α -catenin (RB-089-P, 1:5 dilution, Neomarkers, USA), and β -catenin (RB-090, 1:10 dilution, Neomarkers, USA) were used. Normal ectocervical epithelium was used as a positive control and sections incubated with a negative control serum (Dako, Denmark) were used as negative controls. Immunostaining was evaluated according to the intensity (slight/ strong) and the distribution of staining pattern (homogenous-membranous; heterogenous-cytoplasmic and/or membranous).

Immunostaining pattern was scored as follows: 0= no staining, +1= heterogenous slight staining, +2= homogenous strong staining with respect to the control positive tissue. The intensity and the staining pattern in normal cervical squamous epithelium were regarded as +2 homogenous strong staining.

The chi-square test was used to assess the statistical significance of adhesion molecules expression in relation to preneoplastic and neoplastic squamous lesions.

RESULTS

E-cadherin showed homogenous strong membranous staining in basal, parabasal and intermediate layers of squamous epithelium of the normal ectocervix. Thirteen of the 25 L-SILs (52%) revealed the same staining pattern (+2) but also in superficial layer. Slight cytoplasmic and membranous staining (+1) was observed in 10 (40%) and no staining in 2 L-SILs. No membranous staining was observed in H-SIL, only 5 (20%) showed strong cytoplasmic staining (Figure 1). No homogenous strong staining was seen in invasive squamous carcinomas (Figure 2). The difference in the E-cadherin expression between the squamous lesions of cervix (L-SIL, H-SIL and SCC) was statistically significant ($p=0.0001$). The pattern of E-cadherin expression was also altered in H-SIL and carcinomas.

P-cadherin immunopositivity was seen in the cell membrane of basal and parabasal cells of the normal ectocervical

epithelium with a less intensity than E-cadherin. 12 (48%) L-SILs expressed the same intensity but also in the superficial layers (Figure 3) where 6 had +1 (cytoplasmic, slight) immunostaining and 7 (28%) no staining. P-cadherin was showed only slight and heterogenous cytoplasmic staining in 10 (40%) and strong cytoplasmic staining in 2 (8%) of 25 H-SILs (Figure 4). No strong homogenous staining but only heterogeneous slight staining was observed in 15 squamous carcinomas, the difference of P-cadherin expression between the lesions (L-SIL, H-SIL) and the tumor was also significant ($p=0.009$).

Alpha-catenin staining was cytoplasmic with a strong intensity in the normal and in 11 (44%) of the L-SILs in the full thickness of the epithelium. Thirteen (52%) revealed +1 and one showed no staining. H-SILs revealed 12 (48%) +2 immunostaining and squamous cell carcinomas had only 4 (13%) strong immunostaining ($p=0.0001$). Aberrant nuclear staining of α -catenin was observed in squamous cell carcinomas (Figure 5). Reduced α -catenin expression in H-SIL and squamous cell carcinomas were also associated with decreased E- and P-cadherin expression. Beta-catenin staining was also cytoplasmic and strong in the normal and 17 (68%) of L-SILs (Figure 6), heterogeneous and slight in 7 (28%), and no staining in 1 L-SILs. Beta-catenin expression was strong and homogenous in 11 (44%) H-SILs, and in 11 (36.6%) squamous cell carcinomas ($p>0.05$) (Figure 7). Beta-catenin was expressed through all layers of squamous epithelium in all lesions. The results were summarized in table 1.

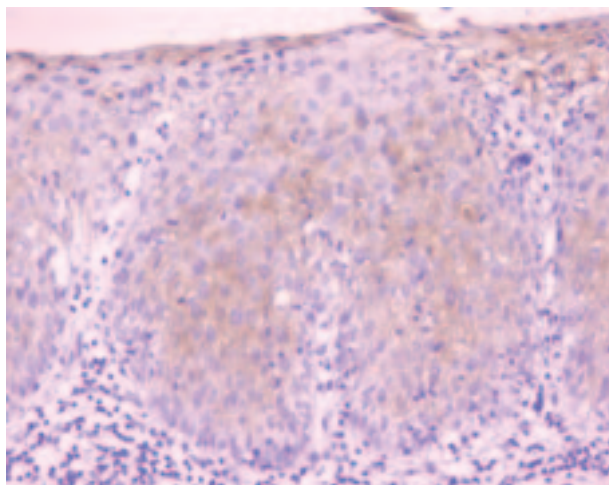


Fig 1. Heterogeneous E-Cadherin positivity in H-SIL (DAB, x200)

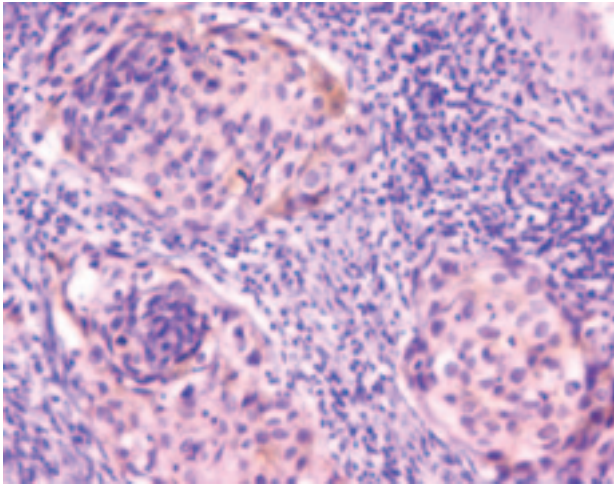


Fig 2. Cytoplasmic E-Cadherin positivity in SCC (DAB, x200)

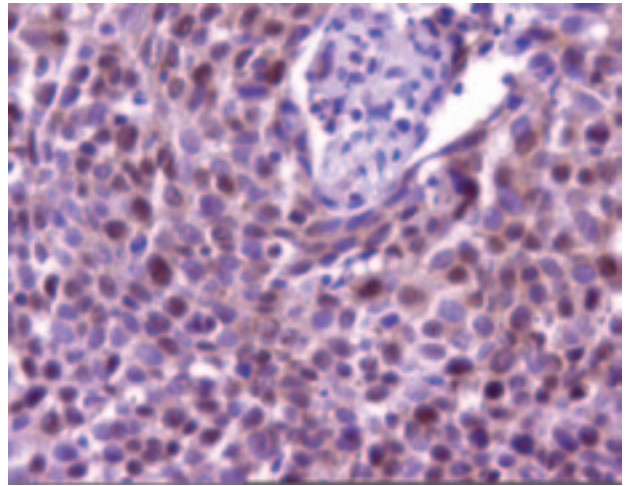


Fig 5. Aberrant nuclear α -catenin positivity in SCC (DAB, x400)

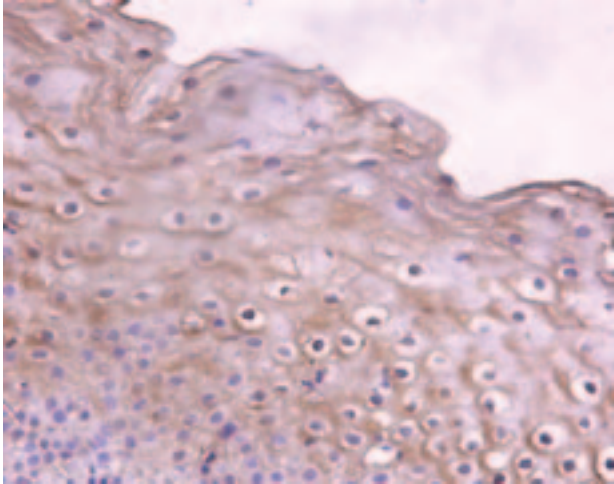


Fig 3. P-Cadherin positivity in L-SIL (DAB, x400)

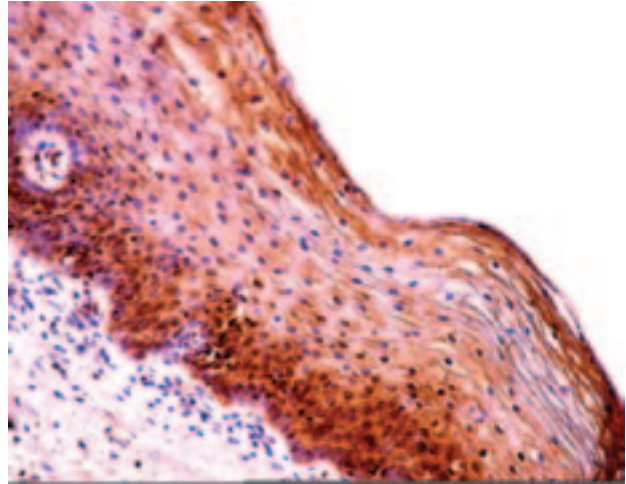


Fig 6. β -catenin positivity in L-SIL (DAB, x200)

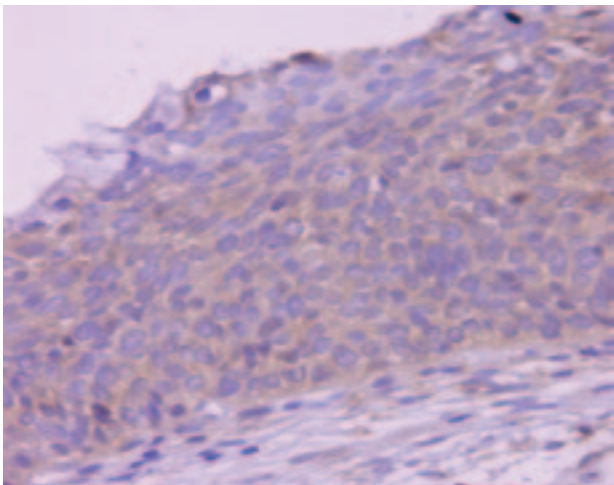


Fig 4. Slight heterogeneous P-Cadherin positivity in H-SIL (DAB, x200)

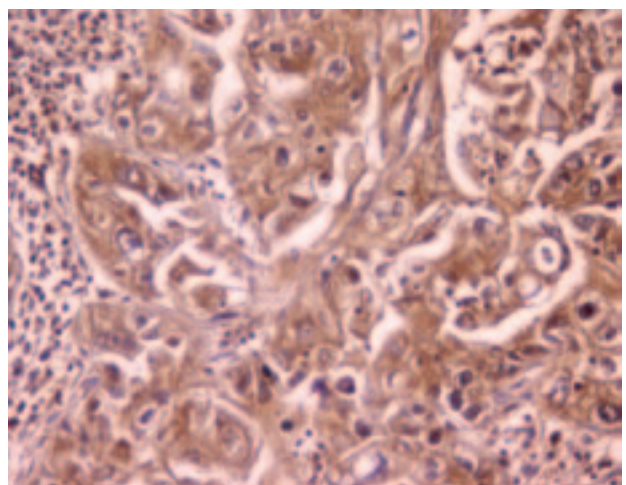


Fig 7. Strong β -catenin positivity in SCC (DAB, x400)

Table 1
Distribution of immunopositivity of adhesion proteins in squamous lesions

Antibody	L-SIL	H-SIL	SCC*	P value
	(positivity %)	(positivity %)	(positivity %)	
E-cadherin	91.7	41.7	6.9	p=0.0001
P-cadherin	75	41.7	37.9	p=0.009
α -catenin	87.5	62.5	31	p=0.0001
β -catenin	79.2	83.3	75.9	p>0.005

*SCC: Squamous cell carcinoma

DISCUSSION

Loss of cell adhesion molecules or altered expression of these molecules plays an important role in tumor progression in epithelial tissues. Cadherins are one of these molecules that mediate via interactions with their cytoplasmic domain catenins which bind to actin cytoskeleton. Cadherin/catenin adherens junction complex is actively involved in signaling, in regulating the assembly of other junctions, and in controlling cell proliferation and motility (5). E-cadherin and its associated cytoplasmic protein α -catenin is one of the main cell adhesion complex in squamous epithelium (3-6). Beta catenin is also an E-cadherin associated cytoplasmic protein but it is also involved in cell proliferation via Wnt signaling pathway (7). P-cadherin is chiefly expressed in reserve cells in cervical epithelium (5). We investigated the expression of E-cadherin, P-cadherin, α -catenin, and β -catenin in cervical squamous cell carcinoma progression from preneoplastic squamous lesions. Like other studies, loss or altered expressions of E-cadherin are observed in our study (2,5,6,8,9). However we found decreased P-cadherin expression as well and loss in H-SIL and in squamous cell carcinomas. Boer et al. (5) observed P-cadherin expression at cell-cell boundaries with an increasing expression from the lower to the upper layers of high-grade SIL.

Though we revealed α -catenin loss in the progression of squamous lesions to carcinoma, aberrant nuclear expression was seen in some squamous cell carcinomas. Most of the studies mentioned loss of α -catenin in squamous cell

carcinomas of cervix (5,6,8). No difference was observed in the β -catenin expression between the developing squamous lesions. Strong cytoplasmic expression of this molecule in H-SIL and in squamous cell carcinomas might be related to its role in cell proliferation. Furthermore, Moon et al. (3) disclosed tyrosine phosphorylation of β -catenin in cervical cancers and suggested that this might restrain the adhesive function of cadherin-catenin complex in tumor progression.

We found altered and absent expression of E-, P-cadherin and α -catenin in the progression of squamous lesions of cervix to squamous cell carcinoma. However β -catenin expression in high grade intraepithelial lesions and in carcinomas indicates its action in tumor growth.

ACKNOWLEDGEMENT

This study was sponsored by Akdeniz University Research Fund No: 21.01.0103.02.

References

1. Siitonen SM, Kononen JT, Helin HJ, et al. Reduced E-cadherin expression is associated with invasiveness and unfavorable prognosis in breast cancer. *Am J Clin Pathol* 1996;105:394-402.
2. Inoue M, Ogawa H, Miyata M, et al. Expression of E-cadherin in normal, benign, and malignant tissues of female genital organs. *Am J Clin Pathol* 1992;98:76-80.
3. Moon HS, Choi EA, Park HY, et al. Expression and tyrosine phosphorylation of E-cadherin, α - and β -Catenin, and epidermal growth factor receptor in cervical cancer cells. *Gynecol Oncol* 2001;81:355-9.
4. Kumar V, Abbas AK, Fausto N, editors. Neoplasia. In: Robbins and Cotran pathologic basis of disease. 7th ed. Philadelphia: Elsevier Saunders, 2004,304.
5. Boer Cj, van Dorst E, van Krieken H, et al. Changing roles of cadherins and catenins during progression of squamous intraepithelial lesions in the uterine cervix. *Am J Pathol* 1999;155:505-15.
6. Carico E, Atlante M, Bucci B, et al. E-cadherin and α -catenin expression during tumor progression of cervical carcinoma. *Gynecol Oncol* 2001;80:156-61.
7. Pereira-Suarez AL, Meraz MA, Lizano M, et al. Frequent alterations of the beta-catenin protein in cancer of the uterine cervix. *Tumour Biol* 2002;23:45-53.
8. Denk C, Hulsken J, Schwarz E. Reduced gene expression of E-cadherin and associated catenins in human cervical carcinoma cell lines. *Cancer Lett* 1997;120:185-93.
9. Rodriguez-Sastre MA, Gonzalez- Maya L, Delgado R, et al. Abnormal distribution of E-cadherin and beta-catenin in different histologic types of cancer of the uterine cervix. *Gynecol Oncol* 2005;97:330-6.