

Primary intracranial solitary melanoma: A rare case with long survival

CEM ÖNAL¹, GÖKHAN ÖZYİĞİT², SERAP AKYÜREK³, UĞUR SELEK², ENİS ÖZYAR², İ. LALE ATAHAN²

¹Başkent University Faculty of Medicine, Department of Radiation Oncology, ²Hacettepe University Faculty of Medicine, Department of Radiation Oncology, ³Ankara University Faculty of Medicine, Department of Radiation Oncology, Ankara-Turkey

ABSTRACT

Although primary intracranial melanoma is rare and the life-expectancy is quite short, we presented a rare case who initially presented 23 years ago with posterior fossa primary malignant melanoma and remained without disease after proper management for more than 17 years with combined treatment including surgery, radiotherapy, and chemotherapy. [Turk J Cancer 2006;36(4):185-187].

KEY WORDS:

Malignant melanoma, central nervous system, survival

INTRODUCTION

Intracranial melanomas are often complicated to diagnose with differential diagnosis of other pigmented lesions like pigmented meningioma, schwannoma, medulloblastoma, choroid plexus papilloma, astrocytoma and pituitary tumors. Primary malignant melanoma is very rare and the other sites of possible primary melanoma in the body should be excluded by clinical and radiological examination (1). We portray a single case who initially presented 23 years ago with posterior fossa primary malignant melanoma and remained without disease after proper management for more than 17 years.

CASE REPORT

The patient is a 38-year-old man who had initially presented in February 1980 with one month history of rapidly worsening symptoms of headache, vomiting, and ataxia. A posterior fossa mass lesion had been detected and he underwent gross total resection of this lesion which was reported as malignant melanoma. Clinical and radiological search for any other site of melanoma in the body was negative. Investigations included chest radiograph, ocular examination, ultrasonography of

abdomen and barium enema. Subsequently, the patient received adjuvant external beam irradiation to posterior fossa in the dose of 60 Gy (40 daily fractions, 1.5 Gy/fraction). He also received adjuvant methyl-CCNU chemotherapy.

He has been alive with no evidence of disease in his follow-up until March 1997 when he was admitted to hospital with nausea, vomiting and severe headache. Cranial magnetic resonance imaging (MRI) demonstrated an expansive mass lesion (hyperintense on T1WI and relatively hypointense on T2WI) in left temporooccipitoparietal location (Figure 1). The lesion was completely excised with postoperative histopathological diagnosis of malignant melanoma. Clinical and radiological search for any possible site of primary melanoma in the body was negative with normal findings of thoraco-abdominopelvic computed tomography. Symptoms of increasing intracranial pressure developed 2 weeks after his surgery. Emergency cranial MRI revealed diffuse intracerebral metastasis with multiple lesions. Therefore, steroid treatment for edema and CCNU-interferon chemotherapy were initiated. The patient died due to diffuse intracranial dissemination.

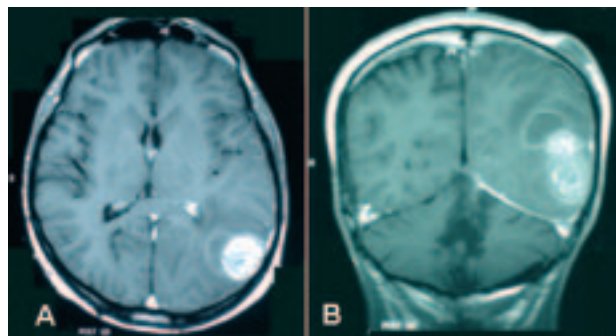


Fig 1 (A,B). (A): Sagittal magnetic resonance imaging view of malign melanoma in occipital lobe, (B): Coronal magnetic resonance imaging view of malign melanoma in occipital lobe

DISCUSSION

Metastasis from the extracranial primary melanoma is more frequent to appear in the brain and is the third most common site of intracranial metastasis after carcinoma of breast and lung (1). However, primary intracranial melanomas are exceptionally rare presenting either solitary or of diffuse variety (2). Our case was a primary solitary melanoma presented in posterior fossa.

Primary melanocytic neoplasms are rare lesions arising from normally occurring leptomenigeal melanocytes (3). Current embryologic data suggests a common origin of melanocytes originating from the neural crest elements normally found within the basal layer of the epidermis and the leptomeninges covering the base of the brain and the brain stem (4-6). Thus, these cells commonly cluster in the pons, cerebellum, cerebral peduncles, medulla, interpeduncular fossa, and inferior surfaces of the frontal, temporal, and occipital lobes (5,7,8). These neoplasms are generally divided into three main types, including diffuse melanosis, meningeal melanocytoma, and primary malignant melanoma. The prognosis in case of solitary primary intracranial melanomas depends upon the degree of mitosis, leptomenigeal dissemination, extent of surgical excision and location of the tumor (1). Diffuse leptomenigeal melanomas mainly appear in children and may be part of neuro-cutaneous melanosis complex or phakomas (9). These may present with features of raised intracranial pressure, cranial nerve palsies and meningism (1). But focal melanomas like our case present as leptomenigeal or dural based neoplasms and are more common in adults.

Yamane et al. (10) stated a major difference of mean survival between solitary diffuse leptomenigeal melanoma cases with 20.7 months and 6.7 months; respectively. Radical tumor resection and use of aggressive whole brain irradiation have been recommended (1,10). The prognosis and long term survival interval were reported to be longer (19.6 ± 2.3 months) with a radical tumor resection and shorter (9.3 ± 2.4 months) with only a biopsy or partial tumor excision (1). Radical approach

in our case with gross total tumor resection followed by external beam radiotherapy to posterior fossa up to 60 Gy and adjuvant chemotherapy established a surprising disease-free duration for 17 years.

Metastasis from primary intracranial melanomas to lungs, spleen, pancreas and kidneys although rare, have been reported in the literature, while we have not observed any systemic metastasis in long follow up of our case (11). However, a second primary melanoma in

temporoparietal region emerged 17 years after initial posterior fossa melanoma and developed to disseminate diffusely even after gross total resection.

In conclusion, aggressive adjuvant treatment including localized radiotherapy and/or chemotherapy after gross total resection of a solitary primary melanoma seems to be a constructive way in decision making of proper management in shaping the emerging literature.

References

1. Baena RR, Gaetani P, Danova M. Primary solitary intracranial melanoma: case report and review of literature. *Surg Neurol* 1992;38:26-37.
2. Kiel FW, Starr LB, Hansen JL. Primary melanoma of the spinal cord. *J Neurosurg* 1961;18:616-29.
3. Aichner F, Schuler G. Primary leptomeningeal melanoma: diagnosis by ultrastructural cytology of cerebrospinal fluid and cranial computed tomography. *Cancer* 1982;50:1751-6.
4. Vanzielegem BD, Lemmerling MM, Van Coster RN. Neurocutaneous melanosis presenting with intracranial amelanotic melanoma. *AJNR Am J Neuroradiol* 1999;20:457-60.
5. Faillace W, Okawara SH, McDonald JV. Neurocutaneous melanosis with extensive intracerebral and spinal cord involvement. *J Neurosurg* 1984;61:782-5.
6. Leaney B, Rowe P, Klug G. Neurocutaneous melanosis with hydrocephalus and syringomyelia. *J Neurosurg* 1985;62:148-52.
7. Alwatban J, Tampieri D, Salazar A, et al. MR of leptomeningeal melanocytosis in a patient with neurofibromatosis. *J Comput Assist Tomogr* 1997;21:38-40.
8. Desai AP, Bhatt AD, Parab MH. Primary melanoma of the leptomeninges. A report of two cases. *Indian J Cancer* 1982;19:161-4.
9. Hoffman HJ, Freeman A. Primary malignant leptomeningeal melanoma in association with giant hairy nevi. Report of two cases. *J Neurosurg* 1967;26:62-71.
10. Yamane K, Shima T, Okada Y. Primary pineal melanoma with long-term survival: case report. *Surg Neurol* 1994;4:2433-7.
11. Glasauer FE, Yuan RHP. Intracranial tumors with extracranial metastasis. Case report and review of the literature. *J Neurosurg* 1963;20:474-93.