

# Gastric parietal cell carcinoma: Report of a case and review of the literature

ALPER ÇELİK<sup>1</sup>, SUAT KUTUN<sup>1</sup>, MUHAMMED CEM KOÇKAR<sup>2</sup>, NURDAN MENĞİ<sup>2</sup>, IŞIN PAK<sup>3</sup>,  
ABDULLAH ÇETİN<sup>1</sup>

Ankara Oncology Hospital, Departments of <sup>1</sup>General Surgery, <sup>2</sup>Gastroenterology and <sup>3</sup>Pathology, Ankara-Turkey

## ABSTRACT

Gastric malignancies arising from parietal cells are an unusual subgroup with favourable prognostic outcomes. We hereby described the clinical and pathological features of a 50 years-old male patient, together with the review of the literature. [Turk J Cancer 2007;37(1):31-33]

## KEY WORDS:

Gastric cancer, parietal cell

## INTRODUCTION

Adenocarcinomas consist almost 95% of all primary gastric neoplasms. Rare histological variants including hepatoid carcinoma, choriocarcinoma, paneth cell carcinoma, small cell carcinoma, neuro-endocrine carcinoma, gastric carcinoma with rhabdoid or lymphoid features and parietal cell carcinoma have been reported. To date, 16 cases of parietal cell carcinoma have been reported (1-8).

## CASE REPORT

A 50 years-old man applied to the clinic with weight loss (7-8 kilograms/4 months), early satiety and epigastric pain. His complaints lasted for more than 3 months, but physical examination was normal. Upper endoscopy revealed the presence of an ulcero-vegetative swelling located at the gastroesophageal junction (35<sup>th</sup> centimeter). Gastric cardia was irregular and the tumor was invading the cardia. Multiple biopsies were taken. The pathology of the endoscopic material was poorly differentiated adenocarcinoma.

Preoperative complete blood count, biochemical analysis, chest-XR, abdominal ultrasound, tumor markers, and other routines were normal. Preoperative thoraco-abdominal computed tomography (CT) revealed thickening of the gastric cardia and multiple paraaortic and pericoeliac lymphadenopathy.

The patient was operated on 25 July 2002. On exami-

nation the tumor was originating from gastric cardia and also was fixed to the left diaphragmatic crus, with multiple paraaortic and celiac lymphadenopathy.

Palliative total gastrectomy, with macroscopic residual tissue, was performed. Reconstruction was done by an omega ans, end-to side esophagojejunostomy. Frozen section examination of the upper surgical margin was positive.

Large areas of neoplastic tissue, invading serosal layer through mucosa and submucosa, consisting of pleomorphic-nucleated cells with large-granulated cytoplasm, thin chromatin and marked nucleus was detected on microscopic examination (Figures 1, 2). The tumoral tissue ascending through submucosal lymphatics of the oesophagus was assigned to have positive superior surgical margin. Inferior surgical margin was tumor-free.

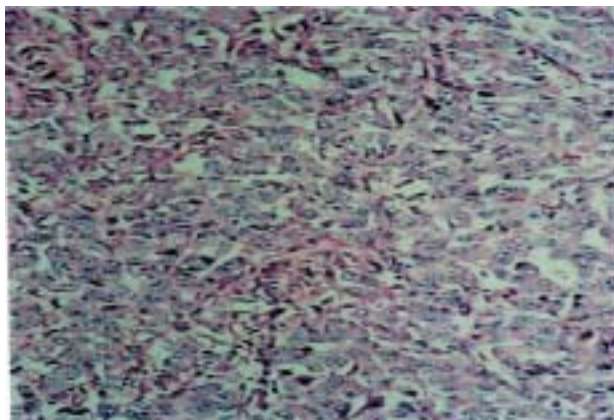


Fig 1. (Hematoxylin&Eosin, x40)

Histochemical staining for mucin with PAS (Periodic acid-Schiff), d-PAS (Periodic acid-Schiff with diastase digestion), Alcian Blue at Ph:1, and Alcian Blue at Ph:2.5

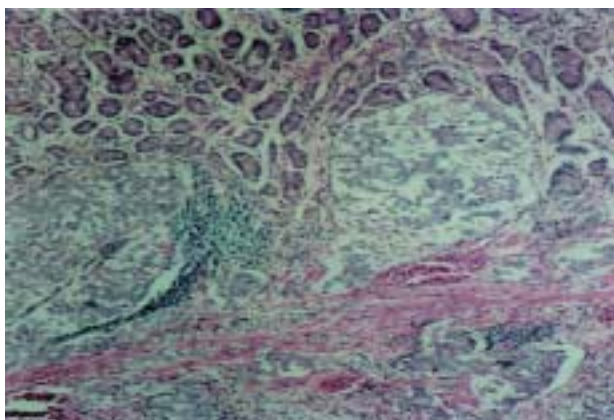


Fig 2. (Hematoxylin&Eosin, x40)

revealed negative. PTAH (Phosphoryungstic acid-haematoxylin) staining was positive.

Immunohistochemical reactivity with CK (cytokeratin), NSE (neuron specific enolase), LMWCK (Low Molecular Weight Cytokeratin) were positive. AFP (Alpha feto protein), LCA (Leukocyte Common Antigen), Snaphophysyn, CEA (Carcinoembryonic Antigen), and Chromogranin stainings were negative. The tumor was diagnosed to be of parietal cell origin.

Thirteen of the 14 lymph nodes from lesser omentum, all of the 5 lymph nodes from celiac region and all of the 4 lymph nodes from greater curvature were metastatic. The spleen was hyperaemic, and no other omental pathology was detected.

In the postoperative course the patient was reoperated due to empyema involving the right hemithorax. Thoracotomy and decortication with unilateral chest tube drainage was applied on 26 August 2003. Pleurodesis was later applied and the case extenated.

The patient was further treated with six cycles of 5-Fluorouracyl-Adriablastina-Cisplatinum chemotherapy, and adjuvant radiotherapy (3800 cGy Cobalt, antero-posterior direction). Plaque atelectasia involving the right hemithorax, but no drainable amount of liquid was detected by the control thorax CT. Upper gastrointestinal endoscopy showed no evidence of recurrence, but perianastomotic edema and luminal hyperaemia were detected (biopsies were negative). The patient is still being followed on an outpatient basis, since April 2003.

## DISCUSSION

Histologically, parietal cell carcinomas of the stomach are well to moderately differentiated tubular adenocarcinomas with very eosinophilic, finely granular cytoplasmic sheets of cells mimicking mesenchymal tumors of smooth muscle origin or large cell lymphoma. Hedenbro and co-workers (5) pointed out the importance of parietal cell carcinoma as a new differential diagnosis for submucosal gastric tumors, which may mimic tumors of leiomyoma/leiomyosarcoma group.

The positivity for Luxol fast blue and PTAH are not adequate for appropriate diagnosis, but might indicate the necessity for further examination. Cafferty et al. (6) reported positive staining for cytokeratin AE1/AE3, in a case with parietal cell carcinoma of the stomach. Rychterova et al. (7) reported two cases, and found both keratins and epithelial membrane antigen negative in parietal cell tumors, and even in normal parietal cells. They found epithelial markers positive in other epithelial cells of the gastric mucosa, and concluded that the diagnosis should be based on electron microscopic findings. They further stated that cases even presenting with advanced disease have better prognosis than other histologic variants.

Byrne et al. (2) and Gaffney (4) also stated good prognosis in gastric carcinoma with parietal cell differentiation, despite advanced primary tumor. Despite the evidence for better prognosis in parietal cell carcinoma, Yang et al. (8) have reported a case of rapid disease progression leading to malignant pleural effusion and death in 2 months time. Their tumor arose in the gastric cardia, without intestinal metaplasia in the nonneoplastic esophageal mucosa. It had a solid growth pattern and extensive lymphatic invasion with undifferentiated and high grade aggressive clinical behaviour.

Immunohistochemical stains for anti-mitochondrial antibodies are strongly positive. Ultrastructurally, the tumor

cells have numerous mitochondria, tubulovesicular endoplasmic reticulum, and occasional intracytoplasmic lumina with associated long microvilli. These histological and ultrastructural features are similar to those of parietal cells in normal gastric fundic mucosa.

Takubo and co-workers (9) have reported 10 cases of unusual types of moderately differentiated tubular adenocarcinomas, with very eosinophilic finely granular cytoplasm. These tumors were histologically parietal cell carcinomas. But different anti-parietal cell antibodies were negative in all cases. They further stated that their tumors might be a different category from previously reported parietal cell carcinomas.

We have diagnosed our case due to histochemical and immunohistochemical findings, as the previously reported patients. Within the light of the advances in immunohistochemistry, the diagnosis of the gastric parietal cell carcinoma would better be based on immunohistochemical reactivity with antiparietal cell antibodies and ultrastructural findings. Addition of these two methods might also explain the heterogeneity of this unusual type of tumor.

---

## References

- 1) Barbosa AJ, Nogueira AM, Leite VH, et al. Parietal cell carcinoma of the stomach and Menetrier's disease. *Arq Gastroenterol* 1987;24:36-40.
- 2) Byrne D, Holley MP, Cuschieri A. Parietal cell carcinoma of the stomach: association with long-term survival after curative resection. *Br J Cancer* 1988;58:85-7.
- 3) Capella C, Frigerio B, Cornaggia M, et al. Gastric parietal cell carcinoma. A newly recognized entity: light microscopic and ultrastructural features. *Histopathol* 1984;8:813-24.
- 4) Gaffney EF. Favourable prognosis in gastric carcinoma with parietal cell differentiation. *Histopathology* 1987;11:217-8.
- 5) Hedenbro JL, Hagerstrand I, Rychterova V. Parietal cell carcinoma: A new differential diagnosis for submucosal gastric tumors. *Endoscopy* 1990;22:47-8.
- 6) Robey-Cafferty SS, Ro JY, Mckee EG. Gastric parietal cell carcinoma with an unusual lymphoma-like histologic appearance: report of a case. *Mod Pathol* 1989;2:536-40.
- 7) Rychterova V, Hagerstrand I. Parietal cell carcinoma of the stomach. *APMIS* 1991;99:1008-12.
- 8) Yang GY, Liao J, Cassai ND, et al. Parietal cell carcinoma of the gastric cardia: Immunphenotype and ultrastructure. *Ultrastruc Pathol* 2003;27:87-94.
- 9) Takubo K, Honma N, Sawabe M, et al. Oncoecytic adenocarcinoma of the stomach. *Am J Surg Pathol*. 2002;26:458-65.