

Primary extrauterine adenosarcoma: Report of 2 cases

BİLGE CAN¹, TÜRKAN KÜÇÜKALİ¹, ALİ AYHAN², ÖZAY ÖZKAYA¹, TEKİN DURUKAN²

Hacettepe University Faculty of Medicine, Departments of ¹Pathology and ²Gynecology and Obstetrics, Ankara-Turkey

ABSTRACT

Müllerian adenosarcoma is a rare neoplasm and has different clinical behavior according to localization and grade of stromal component. Generally, the tumor can be expected to recur or metastasize. Patients with adenosarcoma can have long-standing endometriosis, but direct relation with this tumor and endometriosis is not clear on the literature. Two premenopausal women with abdominal pain and pelvic mass underwent radical operation and were reported as primary extrauterine adenosarcoma. In this report, we emphasized the importance of histological features of these tumors. [Turk J Cancer 2008;38(1):26-29]

KEY WORDS:

Extrauterine adenosarcoma, mixed mesodermal tumor, endometriosis

INTRODUCTION

Clement and Scully (1), in 1974, first described “müllerian adenosarcoma of the uterus”. Adenosarcomas occur at any age, including adolescents (the median age is 71 years for uterine tumors and 49 years for extrauterine tumors) (1-3). Adenosarcomas contain benign müllerian type glands and generally low-grade sarcomatous stroma that resembles stromal sarcoma. Differential diagnosis of adenosarcomas is adenofibroma (a benign entity) and carcinosarcoma (malignant mixed müllerian tumor; a malignant entity with worse prognosis). The treatment of adenosarcoma is maximal cytoreduction aimed surgery (2). Adjuvant therapy has been directed at the high grade sarcomatous component if present (2,3). We report two different extrauterine adenosarcomas one with high-grade, the other with low-grade stromal component.

CASE REPORTS

Case 1

A 49 year-old multiparous woman presented with low-abdominal pain. At patient's history, there were two operations, unilateral left salpingo-oophorectomy in 1981 and cystectomy of right ovary in 1983 for endometriosis. A large pelvic mass was diagnosed on pelvic examination and confirmed on ultrasound. There was no evidence of regional and distant metastatic disease on computed tomography (CT) scanning. She underwent total abdominal hysterectomy, right salpingo-oophorectomy and tumor resection. There was a big mass (19cm) in pouch of Douglas. There were extensive adhesions between the neoplasm and the

uterus, uterine cervix and adnexial structures. Frozen section was reported as “malignant mesenchymal neoplasm”.

Macroscopically, tan-brown solid mass on cut-surface revealed large hemorrhagic and necrotic areas. Histologically, the mass revealed a malignant stroma and benign müllerian-type (endometrial, mucinous and squamous) glands. Glandular part was minimum and scattered in the stroma (Figure 1A). Stromal component was overtly sarcomatous. Mitotic activity showed differences in different areas and heterologous components (1-6 per 10 high-power field). Ki-67 proliferating index also showed differences (Figure 1B). Lipomatous, leiomyomatous and cartilaginous areas -heterologous elements- were found (Figure 1C). There were foci of endometriosis in uterine serosa and ovary; adenomyosis in myometrium was present. All submitted lymph nodes were reactive.

Case 2

A 37 year-old woman (gravida 1, para 1) was admitted to the hospital with abdominal pain. She did not have any gynecologic history. A pelvic mass was diagnosed on pelvic examination and confirmed on USG as vascular solid mass with cystic areas.

Macroscopically, the solid mass was well-circumscribed with a maximum diameter of 13 cm. On cut-surface, the neoplasm was fleshy solid containing numerous cystic structures (Figure 2A). Histologically, it had epithelial and stromal components. Glands were lined by benign-appearing endometrioid cells that were columnar and pseudostratified. Most of the glands were cystic but did not have “leaf-like” configuration. Some of the glands revealed focally simple or complex hyperplastic features. The stroma in large areas appeared loose cellular and looked like endometrial stroma. Based on these features, the tumor looked like an adenomyoma (Figures 2B&C). On frozen section, it had been reported as a benign condition but exact diagnosis could not be given. We made several samplings from different areas. Stromal cells were bland and had low mitotic activity (1 per 10 high-power field). Focal smooth muscle bundles were also present. Stromal cellularity showed condensation around the glands. In these areas the stromal cells didn't showed atypia or high mitotic rate. In two slides on microscopic foci there were overt sarcomatous component (but <25% of all areas) (Figure 2D). The stromal cells were focally but strongly positive for estrogen receptor and CD10. There were also adenosarcomatous foci in left tuba uterina and the ovary. All submitted lymph nodes were reactive.

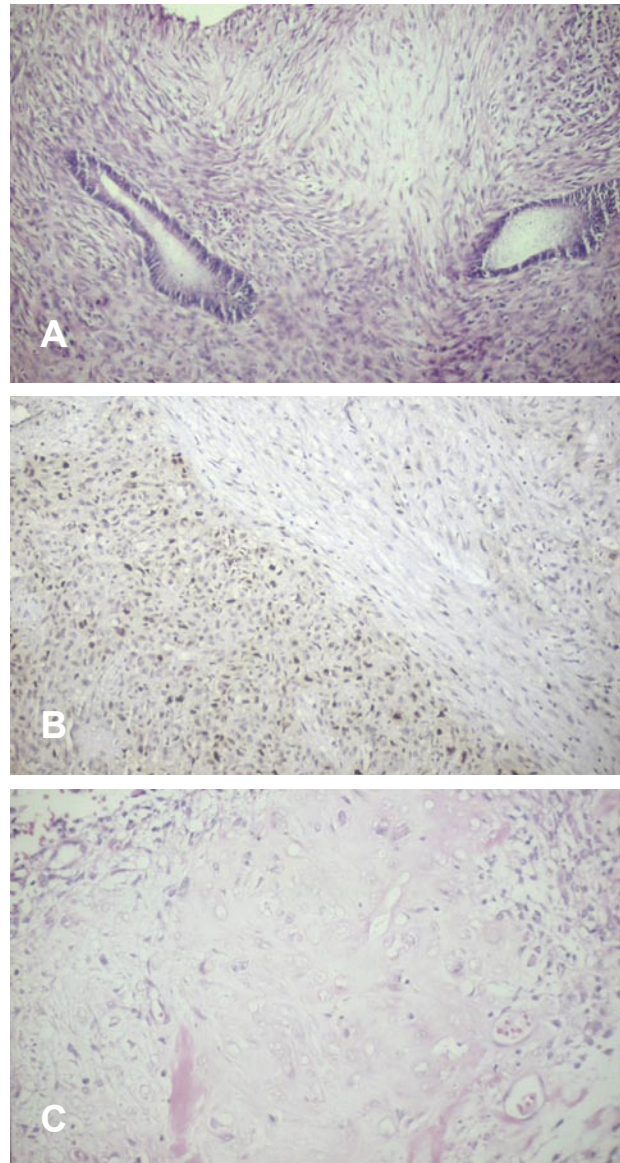


Fig 1. (A,B,C). High-grade adenosarcoma (case 1). (A): A fascicular proliferation of stromal spindle cells and benign endometrial-type glands (H&E, x200), (B): sarcomatous areas with higher Ki 67 proliferation index (immunohistochemically, x200), (C): Chondrosarcomatous component (H&E, x200)

Our patients are peri-menopausal (case 1) and at reproductive age (case 2). Laboratory data were normal. Summary of clinical and pathological characteristics is seen in table 1.

DISCUSSION

Extrauterine müllerian adenosarcomas are rare tumors. They can arise from ovary, fallopian tubes, round ligament, pouch of Douglas, vagina, pelvis even peritoneum, bladder and colon (2,4). Two primary extrauterine adenosarcomas which arose in the pouch of Douglas and pelvis

Table 1
Summary of reported cases

	Case 1	Case 2
Age	49	37
Menstrual cycle	Irregular (premenopausal)	Regular
Endometriosis	+*	-
Symptoms	Abdominal pain	Abdominal pain
Localization	Pouch of Douglas	Pelvis
Maximum diameter	19 cm	13 cm
Epithelial component	Endometrial, mucinous and squamous	Endometrial, (focally hyperplastic)
Stromal component-Grade	High	Low
Mitoses per 10 HPF	1-6	1
Sarcomatous overgrowth	+	-
Heterologous elements	+	-
	Liposarcomatous, Fibrosarcomatous, Chondrosarcomatous	
Diagnosis on frozen section	Malignant mesenchymal tumor	Benign condition
Treatment	Tumor resection & TAH & Right SO & Pelvic lymph node excision	Tumor resection & Left SO & Pelvic lymph node excision
Diagnosis	Adenosarcoma, Heterologous, high grade	Adenosarcoma, Homologous, low grade

* *Left salpingo-oophorectomy twelve years ago and cystectomy from right ovary ten years ago, but no medical or radiation therapy*

HPF: High power field; TAH: Total abdominal hysterectomy; SO: Salpingo-oophorectomy

are described in this report. The majority of adenosarcomas occur in postmenopausal women. But adenosarcomas occur at any age; our two cases were premenopausal. Extrauterine müllerian adenosarcomas occur at younger age than uterine counterparts and have more aggressive clinical behavior because of invasion to adjacent pelvic organs at the time of diagnosis, and recurrence (2-4). In Case 2, it was a pelvic adenosarcoma but there were adenosarcomatous foci in left tuba uterine and the ovary.

In these cases, the glands were lined by endometrial type epithelium and in case 1 glands were lined also by mucinous and squamous epithelium. Carcinomatous component was not observed. In Case 1, heterologous elements were found in high grade sarcomatous areas. We know that Müllerian adenosarcomas differ from malignant mixed müllerian tumors by their less malignant behavior (2,3). So these tumors should be adequately sampled to investigate whether there is a carcinomatous component.

Adenosarcomas may have large areas of low-grade sarcomatous component. Glands are dilated and cystic, and may be hyperplastic with minor atypia. Most adeno-

sarcomas have focally hypercellular stroma, especially in periglandular areas. Periglandular stromal cuffing is a critical diagnostic feature of adenosarcoma (1,2). Stromal cells have bland nuclei so they can be misdiagnosed as endometriosis or as adenofibroma like our case 2. But we were lucky, there were small foci of overt sarcoma that contains high nuclear pleomorphism and atypical mitosis. Stromal cellularity, high mitotic rate and nuclear atypia, if present, are useful criteria in distinguishing from benign conditions. The stromal mitotic counts that have been recommended by Clement and Scully, is 2 or more per 10 high power field (2). Low grade adenosarcomas arising in uterine cervix especially in young patients have favorable prognosis so they should be distinguished from rhabdomyosarcoma. Rhabdomyosarcomas may have loose connective stroma and periglandular rhabdomyoblastic accumulation resembling a low grade adenosarcoma.

Stromal component may contain heterologous elements especially rhabdomyoblasts. When the stroma is sarcomatous, at least 25% of total area, described as "sarcomatous overgrowth" and cases with this feature make up a minor-

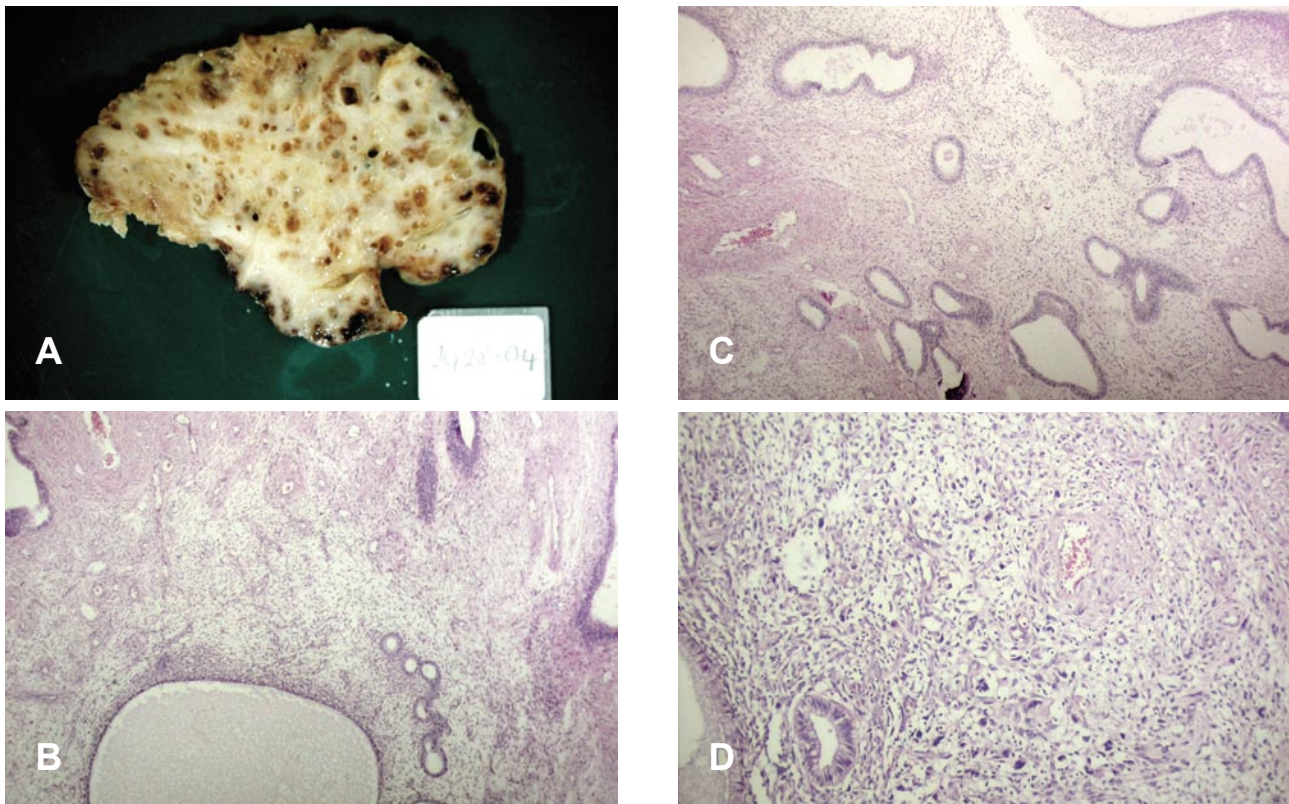


Fig 2. (A,B,C,D). Low-grade adenosarcoma (case 2). (A): cut surface of primary pelvic solid mass with cysts, (B&C): hyperplastic endometrial-type glands with periglandular stromal condensation (H&E, x40), (D): sarcomatous area with nuclear pleomorphism and mitotic figure (H&E, x200)

ity (2). In this group due to the presence of sarcomatous overgrowth, the prognosis is adversely affected.

Immunohistochemical findings of adenosarcomas have been reported previously in a few articles, so we found that estrogen receptors can be positive in stromal cells 8. This finding may be helpful in the treatment of these tumors (3,4,6).

In Case 1, it is difficult to tell that tumor has arisen in foci of endometriosis. We could not show any of Scully's criteria in lots of samples made (5). According to the literature, we must keep on our mind that persistent and

recurrent endometriosis, especially extrauterine forms, may transform to adenosarcoma or be underdiagnosed as "endometriosis" (5,6). In case 1, we couldn't review prior pathology slides for endometriosis.

In conclusion, these cases taught that, diagnosis of adenosarcomas on frozen section has difficulties, underdiagnosis can be a pitfall. To achieve the correct diagnosis of these tumors we must make adequate sampling. Numerous samplings can reveal high-grade sarcomatous areas or carcinomatous focus. So we can explain the difference between pathological appearance and clinical behavior.

References

1. Clement PB, Scully RE. Extrauterine mesodermal (Müllerian) adenosarcoma. A clinicopathologic analysis of five cases. *Am J Clin Pathol* 1978;69:276-83.
2. Eichhorn JH, Young RH, Clement PB, et al. Mesodermal (Müllerian) adenosarcoma of the ovary. A clinicopathologic analysis of 40 cases and a review of the literature. *Am J Surg Pathol* 2002;26:1243-57.
3. Fukunaga M, Nomura K, Endo Y, et al. Ovarian adenosarcoma. *Histopathology* 1997;30:283-7.
4. Visvalingam S, Jaworski R, Blumenthal N, et al. Primary peritoneal mesodermal adenosarcoma: Report of a case and review of the literature. *Gynecol Oncol* 2001;81:500-5.
5. Judson PL, Temple AM, Fowler WC, et al. Vaginal adenosarcoma arising from endometriosis. *Gynecol Oncol* 2000;76:123-5.
6. Liu L, Davidson S, Singh M. Müllerian adenosarcoma of vagina arising in persistent endometriosis: report of a case and review of the literature. *Gynecol Oncol* 2003;90:486-90.