

Multicentric spindle cell hemangioendothelioma of spleen: Case report

SELÇUK MEVLUT HAZİNEDAROĞLU¹, HÜSEYİN AYHAN KAYAOĞLU², FERDA DÜLGER¹, EBRU SERİNSÖZ³, İŞINSU KUZU³, NEZİH ERVERDİ¹

¹Ankara University Faculty of Medicine, Department of General Surgery, Ankara, ²Gaziosmanpaşa University Faculty of Medicine, Department of General Surgery, Tokat, ³Ankara University Faculty of Medicine, Department of Pathology, Ankara-Turkey

ABSTRACT

Malignant mesenchymal tumors of the spleen are rare. The vast majority of primary sarcomas of the spleen are of vascular origin. Hemangioendothelioma, a vascular tumor, is characterized by mild cellular atypia, low mitotic rate and intermediate appearance between hemangioma and conventional angiosarcoma histopathologically. We report herein a case of multicentric splenic hemangioendothelioma presenting together with symptomatic cholecystolithiasis, mild anemia and indirect hyperbilirubinemia, which were recovered after cholecystectomy and splenectomy. [Turk J Cancer 2008;38(1):30-33]

KEY WORDS:

Hemangioendothelioma, spleen, cholecystolithiasis, hyperbilirubinemia, anemia, splenectomy, cholecystectomy

INTRODUCTION

Primary malignant mesenchymal tumors of the spleen are rare and highly aggressive neoplasms with a survival rate of less than one year (1). Although hemangioendothelioma is a vascular tumor, it is characterized by mild cellular atypia and low mitotic rate; an intermediate appearance between hemangioma and conventional angiosarcoma histopathologically (2).

According to our knowledge, this is the second case of multicentric splenic hemangioendothelioma and is the first case presenting together with cholecystolithiasis, anemia and mild indirect hyperbilirubinemia (3).

CASE REPORT

A 24 year-old woman presented with right upper quadrant pain and fatigue. Physical examination was normal except mild tenderness in right upper quadrant. Laboratory investigation revealed normocytic normochromic anemia (hemoglobin, 11.4 g/dl; normal, 12-16 g/dl) and indirect hyperbilirubinemia (0.9 mg/dl; normal, 0.0-0.7 mg/dl). Abdominal ultrasound revealed multiple milimetric stones in the gallbladder and a suspicious mass in spleen. Magnetic resonance imaging (MRI) of upper

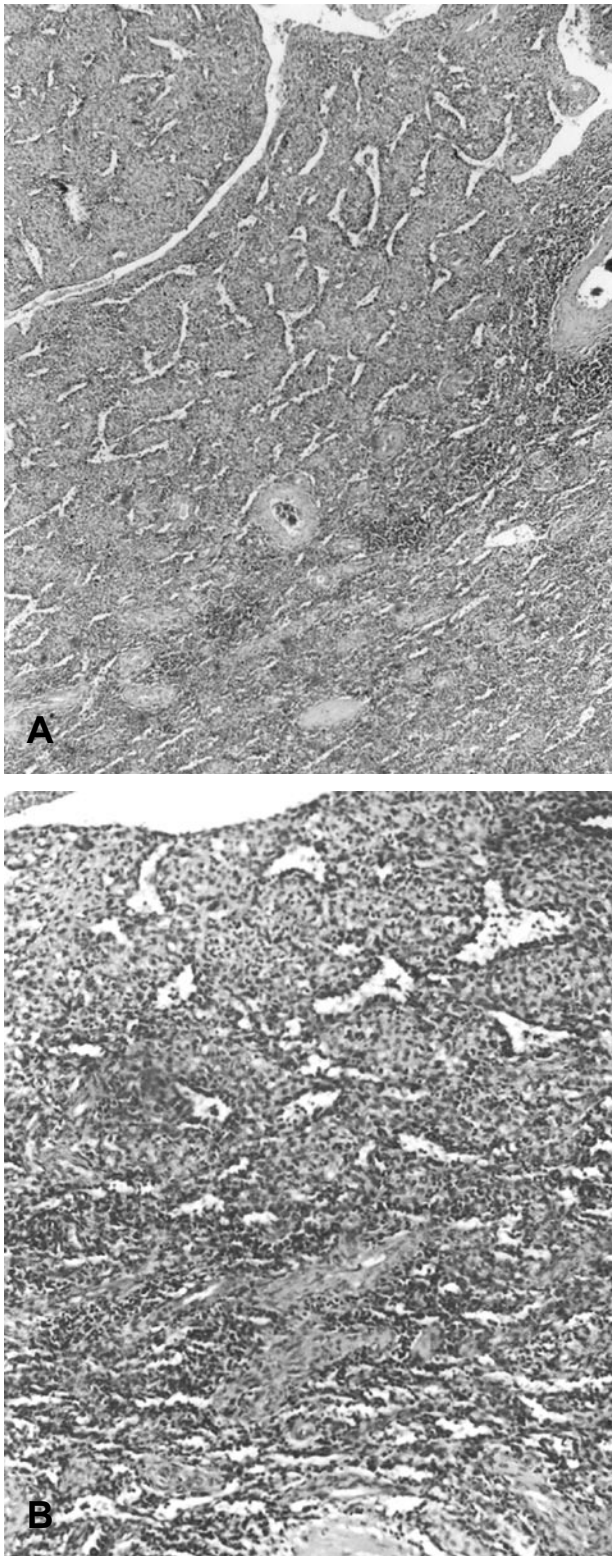


Fig 1. (A,B). (A): Tumor composed of vascular channels lined by plump or spindle endothelial cells and solid tumor cells in between these channels simulating hemangiopericytoma (H&E, x40), (B): On high power examination, some cells of the solid areas showed cytoplasmic vacuolization or cytoplasmic spaces some containing erythrocytes (H&E, x100)

abdomen highlighted this mass as a 4 cm tumor in the upper pole of spleen. There was no evidence of metastasis. The patient underwent cholecystectomy and splenectomy through a midline incision and the operation was straightforward. There was no postoperative complication and her hemoglobin and indirect bilirubin values were within the normal limits during the follow-up in the first, sixth and twelfth months after the surgery. There was no evidence of recurrence in the control abdominal computerized tomography after one year.

Histopathological findings

On macroscopic examination, the spleen was measured to be 15x9x4.5 cm in diameter with a normal configuration. Two distinct non-encapsulated nodules 2 cm away from each other with the diameters of 20x20x10 mm and 9x7x4 mm were detected beneath the capsule on the examination of splenic cross sections. The rest of the spleen was normal. Microscopically, the tumor was composed of vascular channels lined by plump or spindle endothelial cells and solid tumor cells in between these channels simulating hemangiopericytoma (Figure 1A, B). On high power examination, some cells of the solid areas showed cytoplasmic vacuolization or spaces partially containing erythrocytes. There were few atypical cells both among the space lining cells and in the solid areas (Figure 2A, B). However, despite this atypical appearance of the cells, the number of mitotic figures was low. Thin reticulin fibers surrounding individual and group of cells examined on reticulin staining. The tumors revealed an immunohistochemical profile for factor VIII-RA (Figure 3) and CD34 consistent with the immunophenotype of endothelial origin (Figure 4).

DISCUSSION

The term hemangioendothelioma has been used for designation of vascular tumors with intermediate biologic behavior between hemangioma and angiosarcoma. Although they have the ability for local recurrence, these group tumors have significantly low metastasis risk when compared to angiosarcoma. The epithelioid hemangioendothelioma, the most aggressive type of this family, produces distant metastasis and may result in death. The reti-

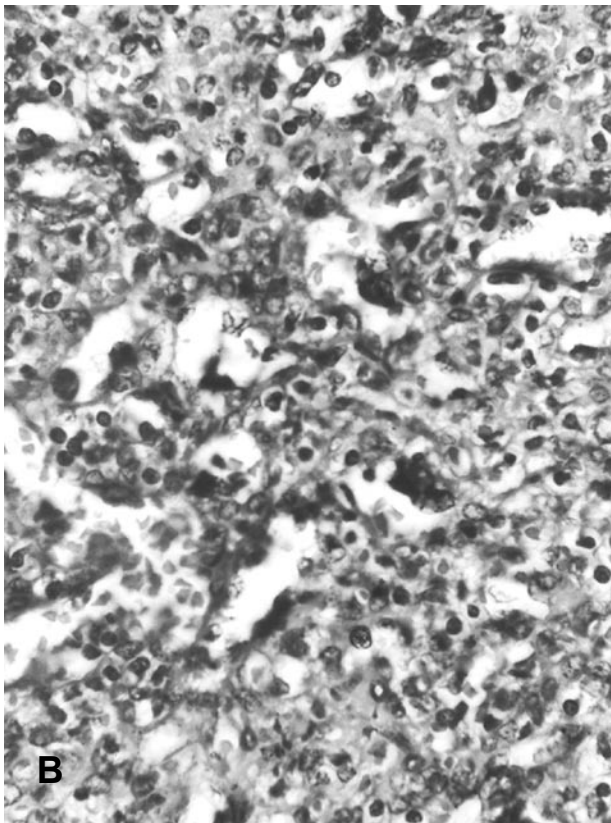
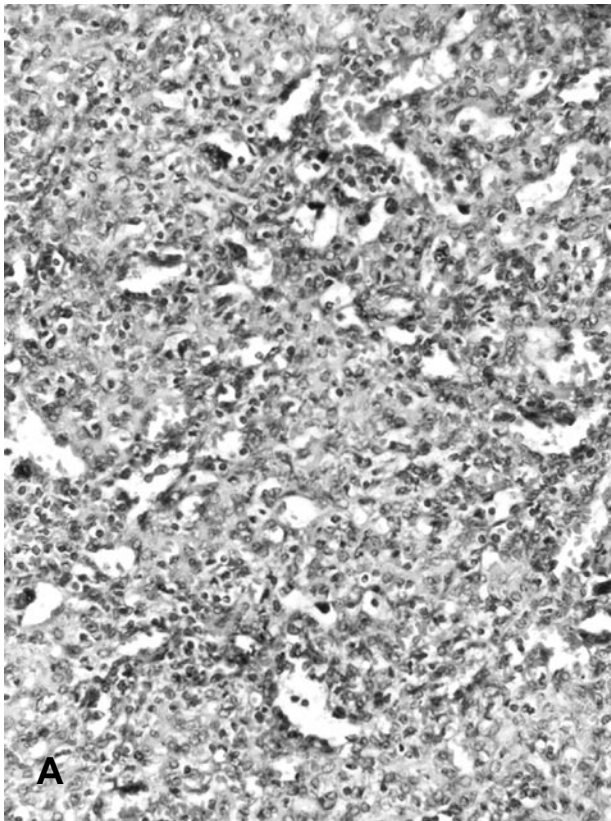


Fig 2. (A,B). There were few atypical cells both among the space lining cells and in the solid areas (A): H&E, x200, (B): H&E, x400

form or Dabska-type hemangioendotheliomas are rarely associated with regional lymph nodes metastasis. The spindle cell hemangioendothelioma has been reclassified by lack of metastasis potential (4,5).

The previous cases of splenic hemangioendothelioma discussed in the literature have similar histopathological and indolent clinical characteristics similar to the forms described at other sites (6-8). Commonly, accompanying clinic situation to the splenic hemangioendothelioma is chronic anemia (9). Functional hyposplenism, spontaneous and traumatic ruptures have been described as single cases (10-12). The other cases reported in literature were asymptomatic and diagnosed incidentally during abdominal imaging for other reasons. However, our patient presented with right upper quadrant pain due to multiple stones in the gall bladder. A mild anemia and indirect hyperbilirubinemia probably related to splenic hyper function were detected.

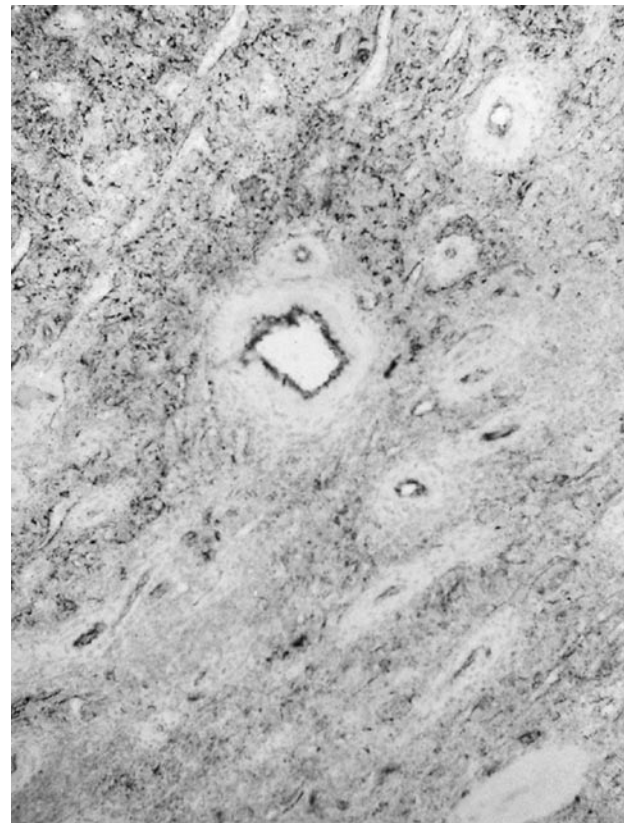

Fig 3. The strong positivity with FVIII-RA revealing endothelial origin of the cells in the solid areas

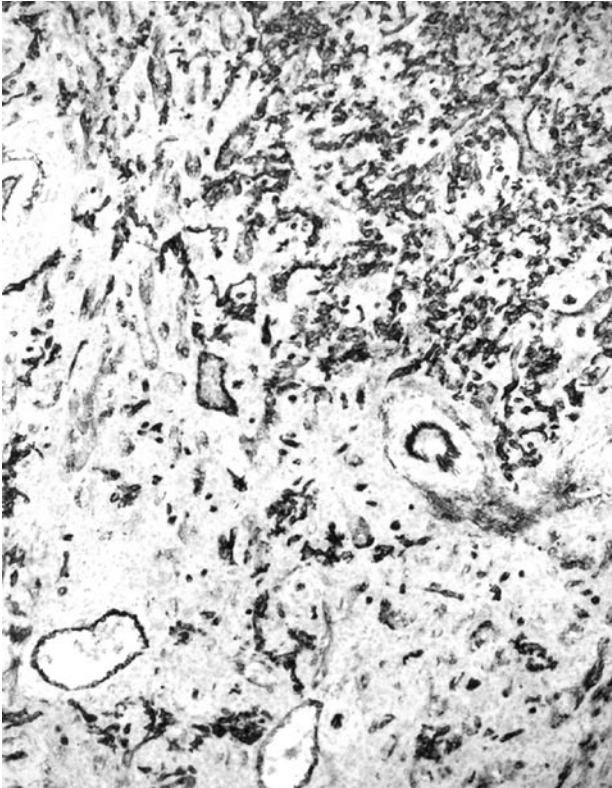


Fig 4. The strong positivity with CD34 revealing endothelial origin of the cells in the solid areas

Although spindle cell hemangioendotheliomas are often multicentric when confined to a single anatomic region, the tumors described in the spleen up to date were not multicentric except a case reported by Heese et al (3). Hemangioendotheliomas are well-separated lesions from healthy parenchyma. In a previously reported case, a primary lesion and multiple intra splenic metastases were described (13). However, in our case, two distinct tumor masses that do not have continuity with each other were detected. According to our knowledge, this is the second multicentric hemangioendothelioma located in the spleen (3). Additionally, this is the first case of hemangioendothelioma presenting with indirect hyperbilirubinemia and anemia both of which recovered after splenectomy.

References

1. Wick MR, Scheithauer BW, Smith SL, et al. Primary nonlymphoreticular malignant neoplasms of the spleen. *Am J Surg Pathol* 1982;6:229-42.
2. Fukunaga M, Ushigome S, Nikaido T, et al. Spindle cell hemangioendothelioma: an immunohistochemical and flow cytometric study of six cases. *Pathol Int* 1995;45:589-95.
3. Heese J, Bocklage T. Specimen fine-needle aspiration cytology of littoral cell angioma with histologic and immunohistochemical confirmation. *Diagn Cytopathol* 2000;22:39-44.
4. Mentzel T. Hemangioendotheliomas--evolution of a concept of a heterogeneous group of vascular neoplasms. *Verh Dtsch Ges Pathol* 1998;82:99-111.
5. Ramer MA, Lumerman H, Kopp W, et al. Epithelioid hemangioendothelioma of the maxilla: case report and review of literature. *Periodontal Clin Investig* 2001;23:31-5.
6. Uchimura K, Nakamuta M, Osoegawa M, et al. Hepatic epithelioid hemangioendothelioma. *J Clin Gastroenterol* 2001;32:431-4.
7. Pigadas N, Mohamid W, McDermott P. Epithelioid hemangioendothelioma of the parotid salivary gland. *Oral Surg Oral Med Oral Pathol Oral Radiol Endod* 2000;89:730-8.
8. Tancredi A, Puca A, Carbone A. Multifocal cerebral hemangio-endothelioma. Case report and review of the literature. *Acta Neurochir (Wien)* 2000;142:1157-61.
9. Kaw YT, Duwaji MS, Knisley RE, et al. Hemangioendothelioma of the spleen. *Arch Pathol Lab Med* 1992;116:1079-82.
10. Budke HL, Breitfeld PP, Neiman RS. Functional hyposplenism due to a primary epithelioid hemangioendothelioma of the spleen. *Arch Pathol Lab Med* 1995;119:755-7.
11. Cerda J, Luque Mialdea R, Soletto J, et al. Segmentary splenectomy of the lower tip because of spontaneous rupture of a splenic hemangioendothelioma in a new-born child--a case report. *Eur J Pediatr Surg* 1994;4:113-5.
12. Goyal A, Babu SN, Kim V, et al. Hemangioendothelioma of liver and spleen: trauma-induced consumptive coagulopathy. *J Pediatr Surg* 2002;37:E29.
13. Tiu CM, Chou YH, Wang HT, et al. Epithelioid hemangioendothelioma of spleen with intrasplenic metastasis: ultrasound and computed-tomography appearance. *Comput Med Imaging Graph* 1992;16:287-90.