

Gastric ring cell carcinoma metastasis to the breast: Two case reports

TİMUÇİN ÇİL¹, ABDULLAH ALTINTAŞ², SEMİR PAŞA², ABDURRAHMAN IŞIKDOĞAN¹

Dicle University, Department of Internal Medicine, Divisions of ¹Medical Oncology and ²Hematology, Diyarbakır-Turkey

ABSTRACT

Metastatic tumors of breast are rare and account only for approximately 2% of all malignant breast cancers. Breast metastasis of stomach's signet ring cell carcinoma (SRCC) is also a very rare condition. Herein, we report two rare cases of gastric SRCC metastasis to the breast. First case is a 63-year-old female patient who was admitted to our clinic with swelling in the left breast and arm with enlarged left axillary lymphadenopathy. She was diagnosed with gastric SRCC a year ago. Second case is a 65-year-old woman diagnosed with gastric SRCC who had undergone total gastrectomy two years ago, and had one-year history of operation for kruckenberg's tumor. This patient was admitted to our clinic with two months history of pain and swelling in the left breast. She was also diagnosed as a gastric SRCC metastasis. [Turk J Cancer 2009;39(2):62-65]

KEY WORDS: Signet ring cell carcinoma, breast adenocarcinoma, metastasis to the breast

CASE 1

A 63-year-old female patient was admitted to our clinic with swelling in the left breast and arm, and enlarged left axillary lymphadenopathy. On physical examination; diffuse swelling of the anterior part of the left breast with erythema, warmth, and tenderness was detected by palpation, which was mimicking partially a peau d'orange phenomenon (Figure 1). Two lymph nodes with a diameter of two centimeters were detected in left axillary region. The infra- and supraclavicular regions and right breast were normal. Patient had undergone radical gastrectomy because of gastric SRCC one year ago, and afterwards she had been treated with adjuvant chemoradiotherapy. After diffuse swelling of left breast, we performed biopsy and in histopathologic examination diffuse infiltration of SRCC was determined (Figure 2). Immunohistochemical staining for ER and PR and CK7 were negative, CK20 and

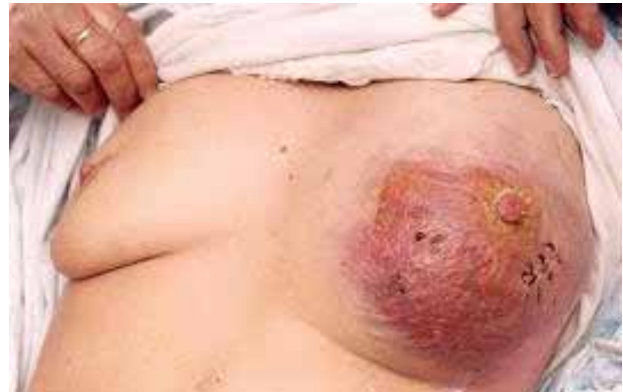

Fig 1. Diffuse swelling of the anterior part of the left breast with erythema warmth, and tenderness on palpation mimicking partially a peau d'orange phenomenon.

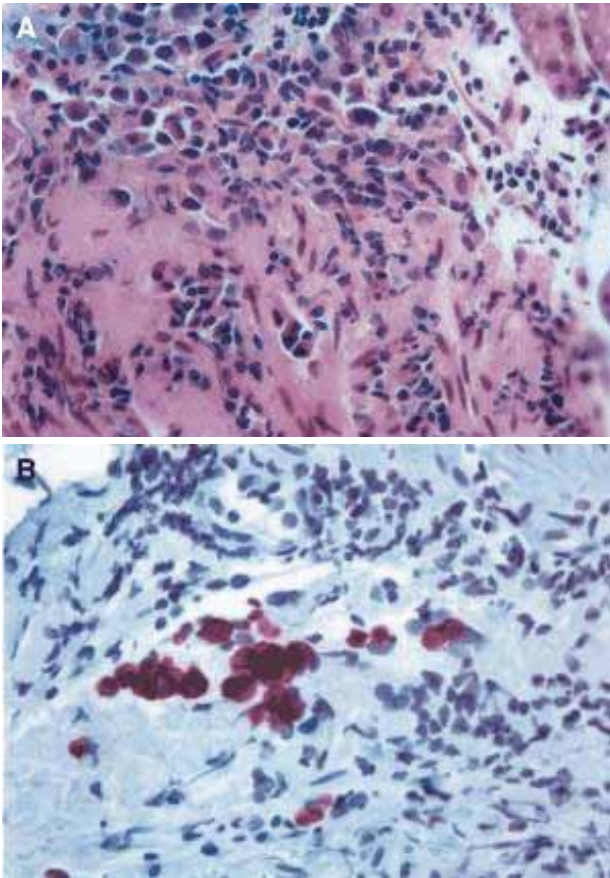


Fig 2. Immunohistochemical staining for estrogen receptors and progesterone receptors were negative. CK20 and CEA were positive in histopathologic examination (x 40).

CEA were found to be positive. Upper gastrointestinal endoscopic evaluation was normal when left breast metastasis has been diagnosed. Computerized tomography of the chest, abdomen, and pelvis did not show any other metastases. The patient started treatment with continuous infusion of fluorouracil based chemotherapy and partial response to the treatment was determined. Four months later, patient had progressed to diffuse lymphangitic lung metastasis, and did not respond to other chemotherapy regimens and she died.

CASE 2

A 65-year-old female patient was admitted with history of pain and swelling mass in the left breast 2 months ago. After endoscopic examination was performed for upper gastrointestinal system screening to the patient who had epigastric pain and dyspepsia, SRCC was diagnosed by endoscopic biopsy in the antrum of stomach two years ago. She was treated with total gastrectomy and no fur-

ther treatment was given. On abdominal and pelvic computerized tomography, right ovarian metastatic mass and ascites were detected a year ago. She had been operated and diagnosed as a kruckenberg tumor. She was first admitted to our clinic because of 2 months history of pain and swelling in the left breast. Physical examination revealed 2x2 cm lump in the upper outer quadrant of the left breast without evidence of axillary or supraclavicular lymphadenopathy. The contralateral breast and axilla were normal. After excisional biopsy, histopathological examination showed SRCC and in immunohistochemical examination ER, PR and CK7 were negative, but the tumor cells showed positivity with CK20 and CEA. The patient received chemotherapy (a combination of docetaxel and carboplatin). After two cycles of chemotherapy, she had partial response to this regimen and after six months of treatment she had multiple liver and lung metastasis but she did not respond to other chemotherapy regimens and she died.

DISCUSSION

Breast adenocarcinoma is the most common tumor of adult women in most part of the world. However, metastatic involvement of the breast by nonmammary malignancy is extremely rare. It has been reported that metastatic tumors account for approximately 1.3–2.7% of all malignant mammary tumors. Sporadic cases do occur, until now, the largest series were published by Georgianos et al. (1). In this report, the files of the histopathology department of the Royal London Hospital were reviewed, including all surgical and postmortem materials during the period 1907–1999. It was found that 450 malignancies (3.2%) had involvement of the breast by secondary tumors, most of which (390 malignancies; 86.7%) were considered metastases from the contralateral breast, it was also found that the remaining 60 malignancies (13.3% of secondary malignancies and 0.43% of total breast malignancies) were nonmammary metastases. Involvement of the breast by hematological malignancies, such as lymphoma and leukemia, were becoming relatively more common. Only 4 of 60 patients had adenocarcinoma of the stomach of the signet ring type (1).

Primary SRCC has been described in many adenocarcinomas; particularly stomach, urinary bladder, urethral,

colorectal, mediastinal and lung tumors. The incidence of SRCC of the stomach was reported to vary from 3.4% in Japan to 39% in western countries (2,3). SRCC of the stomach can be detected at an early stage. Although it rarely involves the entire stomach and seldom invades the gastric wall, peritoneal metastasis often occurs and the prognosis is poor once gastric SRCC has become advanced. Consequently, the most common metastatic sites are peritoneum and regional lymph nodes and the other less metastatic site is liver for advanced gastric SRCC (4). Gastric SRCC occurs more often in women and younger age groups. Our patients were women but they were in an older age group; 63 and 65 years old. Prior to the resection of the primary gastric SRCC we should use diagnostic procedures for gastro-endoscopic and pathological examination. Because the lesions of early gastric SRCC tend to be depressed, gastroendoscopic detection often uses contrast with indigo carmine solution. Moreover, the carcinoma cells are detected easily in biopsy specimens because of their typical enriched intra-cytoplasmic mucin and peripheral compressed nuclei (4).

Antonoli and Goldman (5) reported that 29% of patients with gastric carcinoma had signet ring carcinoma subtype. Metastasis to breast from gastric carcinoma is extremely rare. In the literature only approximately 300 cases of tumor metastases to the breast have been described. Metastasis arising from the gastrointestinal tract is rare and relatively few cases have been reported. One of these gastric SRCC cases, which was a metastasis to breast and clinically presented as an inflammatory carcinoma was published in 1993. The clinical manifestation was highly suggestive of inflammatory carcinoma with red and edematous skin (6). Such clinical findings were also observed similarly in one of our cases. However, in patients who had breast masses diagnosed as SRCC, primary breast SRCC should be distinguished from gastric SRCC metastasis.

Clinically, metastatic lesions are not fully distinct from primary tumors. Thus differentiating primarily from metastatic breast carcinoma is important for rational and

optimum therapy and avoidance of unnecessary radical surgery. Some clinical findings can help us such as, secondary breast cancers being more likely to be freely mobile, round, solitary and free of pain, discharge or skin changes (7). However, secondary breast cancers may have multiple or diffuse involvement. Secondary breast cancers resemble benign lesions, although imaging studies may not demonstrate a mass in mammographic scanning (8). Kwak et al. (9) considered that, the patients who had breast mass might be SRCC in the breast, even though imaging studies haven't indicated any positive findings for SRCC. To distinguish primary breast cancer from SRCC metastasis; immunohistochemical staining for ER or PR are helpful. ER are often present in breast cancers, but more than 20% of primary gastric cancers also have evidence of ER (10). In immunohistochemical studies for metastasis from stomach adenocarcinoma and SRCC, CEA and cytokeratins 20 and 7 are often positive, also ER and PR are negative. The combination of cytokeratin 20 and CEA positive staining in conjunction with negative ER staining strongly supports a diagnosis consistent with a primary gastrointestinal tumor rather than a primary breast carcinoma (11). In our both cases, ER and PR were negative while CEA was positive. There were not any positive findings for primary breast carcinoma in imaging studies.

In conclusion; secondary tumors to the breast are rare, and were reported to account for only approximately 2% of all malignant breast cancers. Clinically, metastatic lesions are not distinct from primary tumors. Thus differentiating primary tumor from metastatic breast carcinoma is important for rational and optimum therapy and avoidance of unnecessary radical surgery. Patients who have breast masses and stomach complaints or gastric carcinoma without any finding in imaging studies, and who have CK20 and CEA positivity with ER, PR and CK7 negativity in immunohistochemical studies, don't have primary breast carcinoma. These patients should be evaluated for stomach ring cell carcinoma.

References

- 1- Georgiannos SN, Aleong JC, Goode AW, et al. Secondary neoplasms of the breast. A survey of the 20th century. *Cancer* 2001;92:2259–66.
- 2- Maehera Y, Sakaguchi Y, Moriguchi S, et al. Signet ring cell carcinoma of the stomach. *Cancer* 1992;69:1645-50.
- 3- Hyung WJ, Noh SH, Lee JH, et al. Early gastric carcinoma with signet ring cell histology. *Cancer* 2002;94:78-83.
- 4- Otsuji E, Yamaguchi T, Sawai K, et al. Characterization of signet ring cell carcinoma of the stomach. *J Surg Oncol* 1998;67:216-20.
- 5- Antonioli DA, Goldman H. Changes in the location and type of gastric adenocarcinoma. *Cancer* 1982;50:775-81.
- 6- Cavazzini G, Colpani F, Cantore M, et al. Breast metastasis from gastric signet ring cell carcinoma, mimicking inflammatory carcinoma. A case report. *Tumori* 1993;79:450-3.
- 7- Miyoshi K, Fuchimoto S, Ohsaki T, et al. A case of esophageal squamous cell carcinoma metastatic to the breast. *Breast Cancer* 1999;6:59-61.
- 8- Alexander HR, Tuurnbull AD. Isolated breast metastases from gastrointestinal carcinomas: report of two cases. *J Surg Oncol* 1989;42:264-6.
- 9- Kwak JY, Kim EK, Oh KK. Radiologic findings of metastatic signet ring cell carcinoma to the breast from stomach. *Yonsei Med J* 2000;41:669-72
- 10- Kojima O, Takahashi T, Kawakami S, et al. Localization of estrogen receptors in gastric cancer using immunohistochemical staining of monoclonal antibody. *Cancer* 1991;67:2401-6.
- 11- Tot T. The role of cytokeratins 20 and 7 and estrogen receptors analysis in separation of metastatic lobular carcinoma of the breast and metastatic signet cell carcinoma of the gastrointestinal tract. *APMIS* 2000;108:467-72.